



## The utility of patch recorders in neonatal ambulatory electrocardiogram recording

### Keywords:

Ambulatory ECG  
Patch recorders  
Neonatal arrhythmia

Ambulatory electrocardiogram (aECG) monitoring is the commonest second line investigation in children with a suspected or known cardiac rhythm problem used to diagnose arrhythmias as well as to determine the efficacy of intervention [1]. The traditional Holter monitor has been the most widely used modality in aECG monitoring. Holter monitors are available only for a duration of 24–48 hours and require the patient to stay in or in close proximity to the healthcare facility as the device needs to be returned for interrogation. This is often a challenge in a large country with significant resource limitations like India. Hence patch aECG recorders are becoming increasingly popular among cardiologists and cardiac electrophysiologists [2]. One such patch based aECG is the Webcardio monitoring system (Gadgeon Smart Systems, Kerala, India). Similar patches have been used in the pediatric population including neonates in the Western world. However, the WebCardio patch is being recommended only in children more than 2 years of age due to lack of data and perceived concerns about the effect of the strong adhesive used in the patch on the infant skin. We report our preliminary experience with the use of Webcardio Holter in 2 neonates with arrhythmias.

A 25-day old neonate weighing 3.4 kg was referred for management of a recurrent tachyarrhythmia. She had multiple episodes of a regular narrow complex tachycardia (Fig. 1 A) each of which terminated with administration of intravenous Adenosine. The baseline electrocardiogram did not show any evidence of ventricular pre-excitation. A diagnosis of atrio-ventricular (AV) reentrant tachycardia (due to a concealed accessory pathway) was made. Dual pharmacotherapy with Sotalol and Digoxin was initiated resulting in control of tachyarrhythmia 72 hours after admission. The neonate was discharged after a further 48 hour in-hospital monitoring during which there was no recurrence of tachycardia. A Webcardio patch was placed prior to discharge. This provided good quality 2 channel recording for 92 hours. The neonate was in sinus rhythm during most of the period. There was a single episode of narrow complex tachycardia with a heart rate of 280 per minute which lasted for 12 minutes and reverted

spontaneously (Fig. 1B and C). The initiation and termination of tachycardia was abrupt and suggested a re-entrant tachycardia similar to the episodes recorded during hospitalization. At follow up, 3 months later, the infant remained symptom free.

A 34-year-old second gravida mother was referred for a fetal cardiac evaluation at 30 weeks gestational age due to an irregular fetal heart rate. The heart was structurally normal. There were frequent premature ventricular contractions (PVC) in trigeminy and bigeminy pattern. This pattern persisted throughout the rest of her pregnancy with occasional couplets noted during ultrasound evaluation. The baby was delivered by normal vaginal delivery at 39 weeks and weighed 3.7 kg at birth. The peri-natal period was uneventful. The rhythm evaluation documented recurrent episodes of non-sustained ventricular tachycardia with a maximum heart rate of 190 per minute lasting 3–20 seconds (Fig. 2A). The baby remained hemodynamically stable and the heart function was normal. He was managed with oral beta-blockers (Propranolol) resulting in control of arrhythmia in the next 12 hours. The baby was monitored in-hospital for 72 hours. During this period, there were occasional episodes of non-sustained ventricular tachycardia and PVC which reduced in frequency. The baby was discharged after a Webcardio patch was placed (Fig. 2 B). This provided 72 hours of good quality recording. There were 4 episodes of non-sustained ventricular tachycardia with iso-rhythmic atrio-ventricular dissociation or 1:1 ventriculo-atrial (V-A) conduction (Fig. 2 C). However, the maximum heart rate was only 143 per minute and no clinical concerns were raised by the parents during this period. There was no difficulty or skin damage while removing the patch in both the neonates.

The indications for aECG monitoring in children are similar to adults. However, there are important concerns regarding the available modalities. Traditional Holter monitors are often too bulky for small children and offer a relatively short duration of ECG recording. Older infants and toddlers are often intimidated by wired Holters. Hence there has been interest among the pediatric cardiac community regarding the use of wireless patch aECG monitoring. A number of devices are available worldwide. The pediatric experience with the Zio XT patch (iRhythm technologies, CA, USA) has been published and included its use in neonates [3,4]. However, the device is not available in India. One of the widely used patches in South India is the Webcardio monitoring system. The device has been shown to provide good quality diagnostic information comparable to a traditional Holter in adults [5]. The anecdotal experience of its use in the pediatric population has been reported to be satisfactory. The Webcardio patch provided good quality recordings in both the neonates on whom the patch was placed. We did not compare the findings on Webcardio to that of a traditional Holter

Peer review under responsibility of Indian Heart Rhythm Society.

<https://doi.org/10.1016/j.ipej.2020.12.001>

0972-6292/Copyright © 2020, Indian Heart Rhythm Society. Production and hosting by Elsevier B.V. This is an open access article under the CC BY-NC-ND license (<http://creativecommons.org/licenses/by-nc-nd/4.0/>).

Please cite this article as: M.R. Krishna, U.N. Sennaiyan and K. Ramanathan, The utility of patch recorders in neonatal ambulatory electrocardiogram recording, Indian Pacing and Electrophysiology Journal, <https://doi.org/10.1016/j.ipej.2020.12.001>

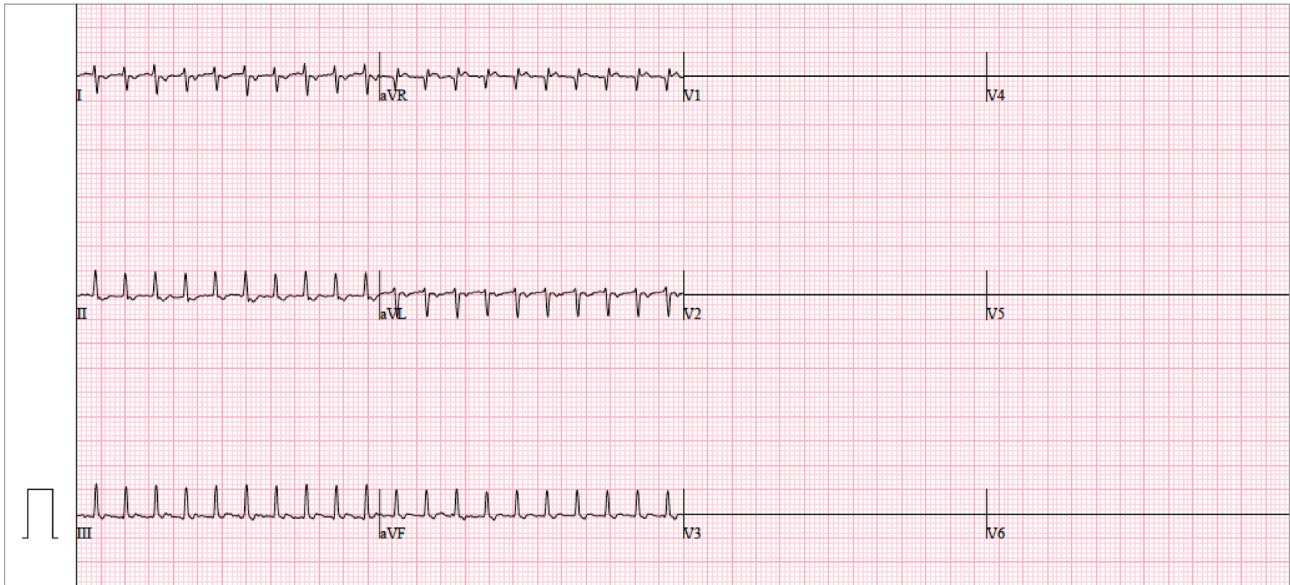


Fig. 1A. Standardized 6 lead ECG of patient 1 demonstrating a regular narrow complex tachycardia with a short R–P interval and a heart rate of 242 per minute consistent with atrio-ventricular reentrant tachycardia.

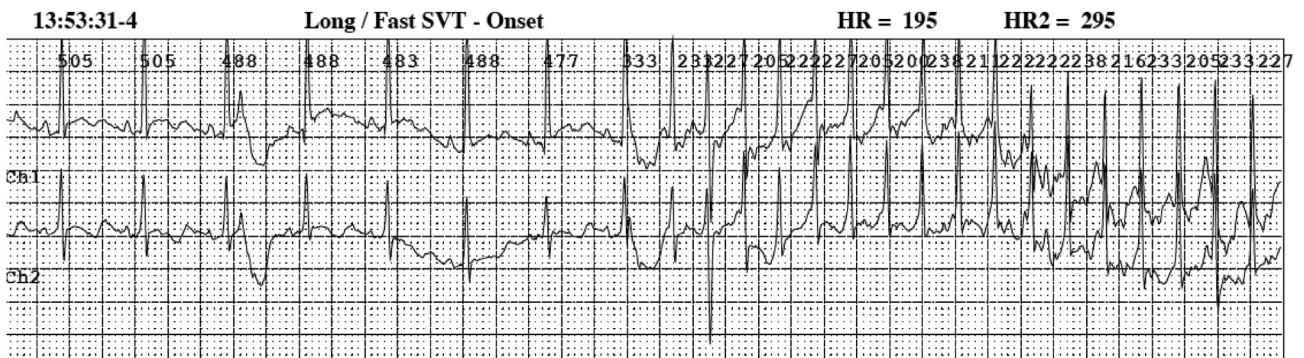


Fig. 1B. Snapshot from the Holter recording of patient 1 demonstrating abrupt onset of tachycardia.

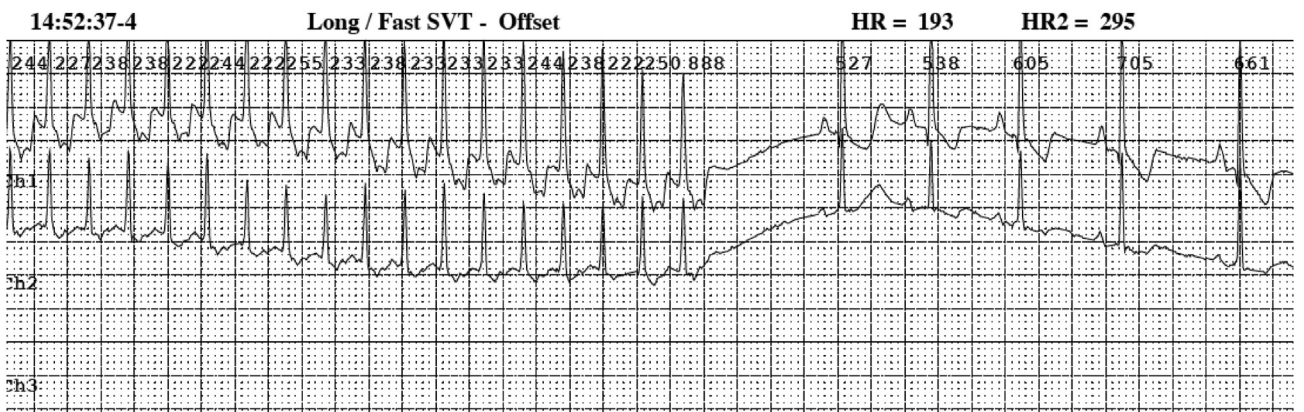
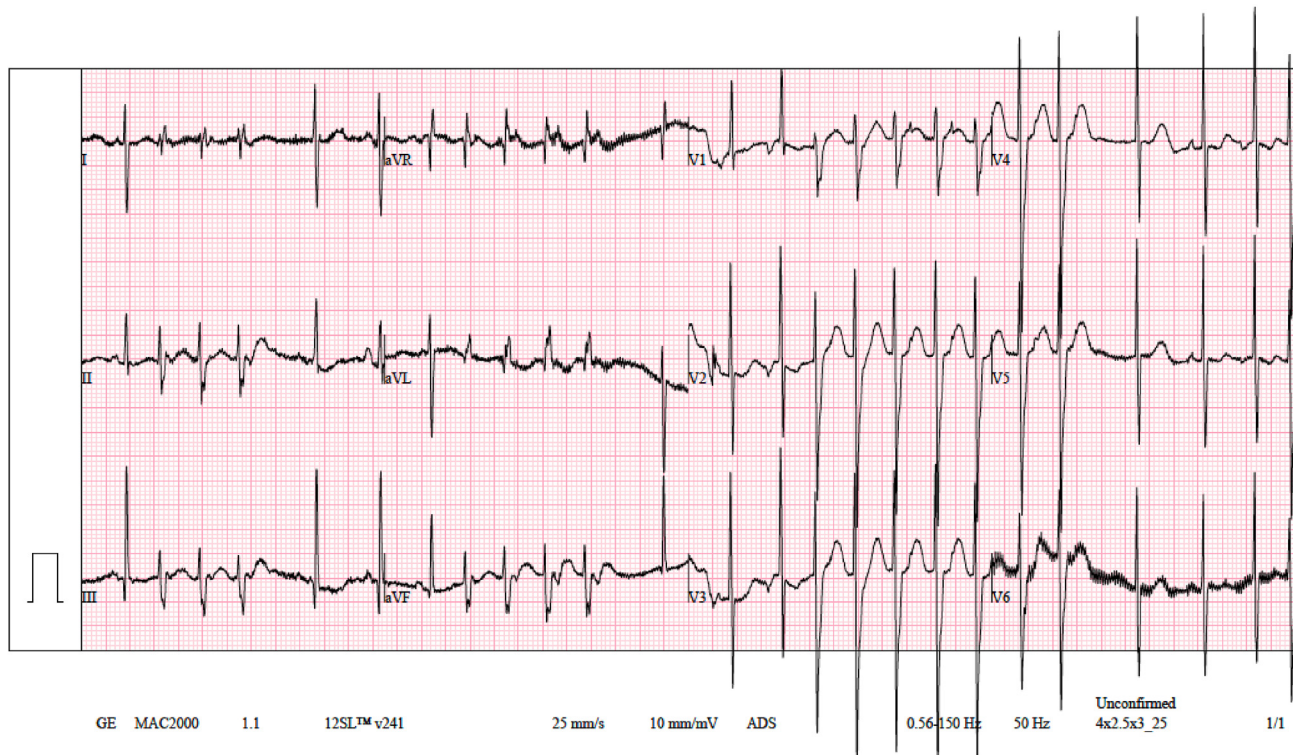
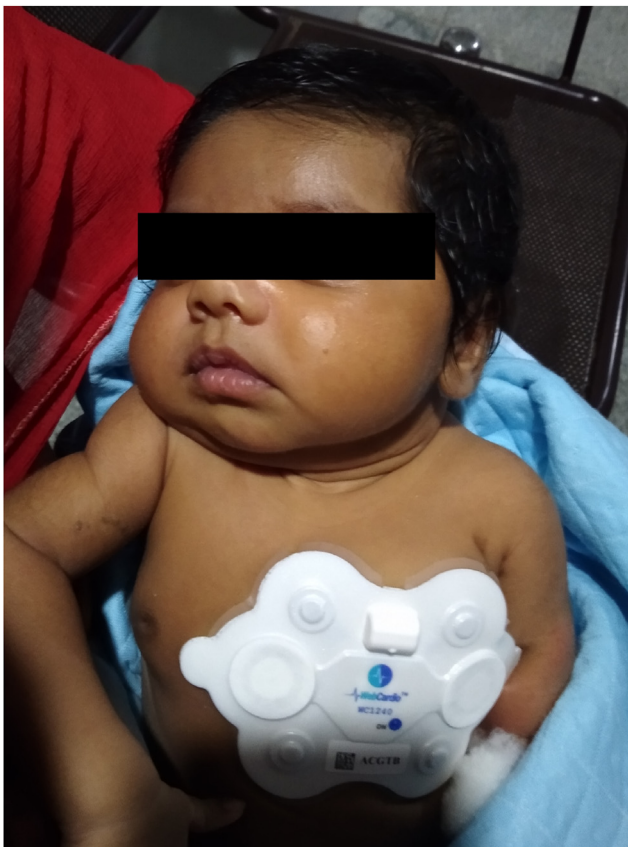

Fig. 1C. - Snapshot from the Holter recording of patient 1 demonstrating an abrupt termination of the tachyarrhythmia consistent with a reentrant mechanism.





**Fig. 2A.** Standardized 12 lead ECG of patient 2 demonstrating a non-sustained tachyarrhythmia with broader QRS complexes and 1:1 ventriculo-atrial conduction.



**Fig. 2B.** Image of the patch recorder placed on the neonate's chest.

or cardiac telemetry simultaneously. The main challenge in obtaining simultaneous recordings is the inability to place both monitors in the small chest surface of the neonate. We hence have to rely on similar information obtained from older patients which has been deemed satisfactory [5]. The arrhythmias detected on Webcardio were similar to the ones detected on ECG monitoring lending further credibility to the results. The aECG recording by capturing the initiation and termination of the tachyarrhythmia helps understand the mechanism of arrhythmia when it is not clear on surface ECG recordings. In the first case, there was abrupt initiation of the arrhythmia and the tachyarrhythmia terminated abruptly with a p wave. This confirmed the AV reentrant mechanism of the arrhythmia.

Our preliminary experience suggests that the device can be used safely in neonates and the quality of recordings are good enough to provide diagnostic information.

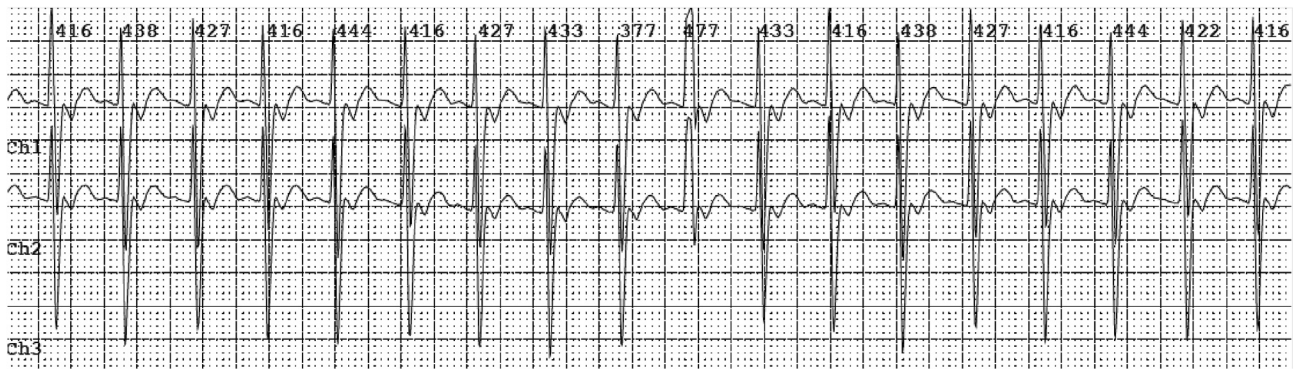


Fig. 2C. Snapshot from the Holter recording of patient 2 demonstrating a tachycardia with 1:1 ventriculo-atrial conduction and a heart rate of 145 per minute.

## Funding

There was no external funding involved in the submitted work.

The data that support the findings of this study are available on request from the corresponding author. The data are not publicly available due to privacy or ethical restrictions.

## Declaration of competing interest

The authors report no conflict of interest with regard to this work.

## References

- [1] 2017 Steinberg JS, Varma N, Cygankiewicz I, Aziz P, Balsam P, Baranchuk A, et al. ISHNE-HRS expert consensus statement on ambulatory ECG and external cardiac monitoring/telemetry. *Heart Rhythm* 2017;14(7):e55–96.
- [2] Fung E, Jarvelin MR, Doshi RN, Shinbane JS, Carlson SK, Grazette LP, et al. Electrocardiographic patch devices and contemporary wireless cardiac monitoring. *Front Physiol* 2015;6:149.
- [3] Pradhan S, Robinson JA, Shivapour JK, Snyder CS. Ambulatory arrhythmia

detection with ZIO(R) XT patch in pediatric patients: a comparison of devices. *Pediatr Cardiol* 2019;40(5):921–4.

- [4] Bolourchi M, Silver ES, Muwanga D, Mendez E, Liberman L. Comparison of holter with Zio patch electrocardiography monitoring in children. *Am J Cardiol* 2020;125(5):767–71.
- [5] Karunadas CP, Mathew C. Comparison of arrhythmia detection by conventional Holter and a novel ambulatory ECG system using patch and Android App, over 24 h period. *Indian Pacing Electrophysiol J* 2020;20(2):49–53.

Mani Ram Krishna\*, Usha Nandhini Sennaiyan  
Dr R.K. Hospital for Women and Children, Thanjavur, Tamil Nadu,  
India

K. Ramanathan  
Maruti Hospital, Trichy, Tamil Nadu, India

\* Corresponding author.

E-mail address: [mann\\_comp@hotmail.com](mailto:mann_comp@hotmail.com) (M.R. Krishna).

20 October 2020  
Available online xxx